

ARS NOSE NEWS OCTOBER 2016

TABLE OF CONTENTS

[President's Report](#)

[Summer Sinus Symposium: Recap](#)

[Annual Meeting Update](#)

[New Resource: ICAR Slide Series](#)

[Rhinology Perspectives: The Recalcitrant Nasal Polyp Patient](#)

[Pan-American Conference Report](#)

[Upcoming RUC Survey: Re-evaluating FESS Codes](#)

[2016 Friends in Research Supporters](#)

[Case of the Quarter](#)

[Thank You to Corporate Supporters](#)

[ARS Contact Information](#)

PRESIDENT'S REPORT

Peter Hwang, MD, FARS

As we wrapped up an outstanding Annual Meeting in San Diego, it was an exciting yet bittersweet moment for me to reflect on the end of my term as President of the society. It has been a true honor to serve the membership and be part of this truly exemplary organization.

With a membership filled with brilliant, passionate, and innovative people, it is imperative that the Society create an environment and a structure that supports, sustains, and encourages continued growth. To this end, I convened the Society's leadership this past June for a strategic planning retreat to prioritize growth areas for the society and to develop a 3-year strategic plan. We identified four areas for further development that would allow us to achieve our goal, which is "Pursuing Global Excellence in Rhinology."

1. Education: We believe the ARS should be the singular resource for rhinology education globally. We are very proud of the intellectual content that we as a Society produce through our scientific meetings, our website, and our journal, the International Forum of Allergy & Rhinology. We now have a task force that will collaborate with the Education Committee to develop strategies to disseminate our intellectual content globally, via the website, social media, and livestreaming, and to innovate our current scientific meeting structure.



2. Advocacy: We believe that the ARS has the responsibility of influencing health care policy as it relates to issues concerning our membership and our patients. We recognize that doing so requires expertise, organization, and focused strategy. We have established two Advocacy task forces: one to focus on quality improvement, which will help the Society to navigate the rapidly evolving landscape of quality metrics; and the second to create an action plan to help the Society become a more politically active and influential player, from the grass roots level to high level political organization.

3. Outreach: Our members are certainly our greatest asset as a Society. We are grateful for the tremendous energy and enthusiasm that all of you bring to your roles as members of our Society. But we also feel that there are many people who would enjoy being part of this great organization who are simply not aware of the benefits of Society membership. Our outreach task force will collaborate with the Membership Committee to create opportunities for community outreach to local otolaryngologists and for international outreach to sister societies in other countries.



4. Finances: The society is extremely fortunate to be in excellent financial health. This is in large part due to the careful stewardship of the leaders who have come before us, and to the tireless efforts of our Development Committee. As we pursue growth opportunities, many of these new initiatives will require funding from the Society. The financial task force will be developing a strategic plan for judicious spending that will promote growth while allowing us to preserve a healthy reserve for the Society.


As you can see, the leadership of the ARS cares deeply about charting a well-defined plan for growth of the Society. As I close out my term as President, I am extremely optimistic at the prospects of our Society to continue to rise in eminence, to lead, and to pursue global excellence in rhinology. I would like to thank all of you for caring deeply about your profession and for your commitment to the ARS.

[Back to top](#)

SUMMER SINUS SYMPOSIUM 2016 RECAP

Rick Chandra, MD
James Palmer, MD
Kevin Welch, MD

On behalf of the program committee, we're thrilled to announce that the 2016 5th Annual Summer Sinus Symposium was an all around success! We packed the Westin Michigan Avenue for a 3-day meeting filled with panels, debates and ancillary symposia. We had our best attendance ever! From all corners of North America, South America, Australia, Africa, Europe and Asia, physicians, residents and allied health partners came to learn and participate in this now global event.



Our Thursday afternoon was filled with cadaver dissections and an evening discussing office-based procedures. We gathered in the main ballroom to hear Dr. David Kennedy's keynote address and ARS leaders who guided panel discussions about managing chronic rhinosinusitis. Dr. Rodney Schlosser led a very extensive cadaver dissection while utilizing the latest tools and techniques.

The Friday night cocktail reception on the 95th floor of the John Hancock Tower for a cocktail reception was well attended and

offered great opportunities to network with peers and industry representatives.

Participants rounded out their experience on Saturday with discussions about preoperative and postoperative management of the sinus patient, coding and medicolegal issues and navigated among three breakout rooms to discuss the management of allergic disease, advanced orbital and skull base disease, topical therapies, functional and cosmetic rhinoplasty, performing office based procedures, and much more.

Next year, this fabulous meeting moves to Washington D.C. at the Omni Shoreham and will be spearheaded into a new era by Drs. Greg Davis, Marc Dubin and Doug Reh. This meeting has been and will continue to be a great success since it is a meeting run by you and for you. So please, join us in Washington DC July 2017! It's a meeting that isn't to be missed.



6th Annual
Summer Sinus Symposium
*The Best Sinus Course in the World:
 Improving Rhinology from Office to OR*
 The ARS has structured this meeting to inform and educate every OTOLARYNGOLOGIST treating nasal and sinus disease.

July 14-16, 2017 *New City!
 New Venue!*
 Omni Shoreham Hotel, Washington, DC

FREE REGISTRATION FOR ARS MEMBERS
 with your Membership Dues!

Not a member? **Join the ARS NOW** and attend the **Summer Sinus Symposium** for **FREE!**

Meeting details are online at:
<http://www.american-rhinologic.org/sss>

Contact: Wendi Perez, ARS Executive Administrator
 Tel: 845.988.1631, Fax: 845.988.1527, wendi@amrhso.com
 ARS, PO Box 495, Warwick, NY 10990 | www.american-rhinologic.org/sss

[Back to top](#)

ARS ANNUAL MEETING UPDATE

John DeGaudio, MD, FARS

President Elect and Program Chair

The fall meeting of the American Rhinologic Society was held at the Manchester Grand Hyatt in San Diego on September 16-17, 2016. The meeting was preceded by the first ARS Resident Sinus Surgery course that was organized and run by Zara Patel, MD and the Education Committee. The course was a great success and filled to capacity. The curriculum featured lectures and cadaveric dissections and was generously supported by Acclarent, Olympus, and Intersect.

Our guest countries were those of the European Union, including the UK, despite the recent Brexit. A wonderful reception was held

on Saturday evening to celebrate our Kennedy lecturer, international guests, and poster viewing.

This year the entire meeting was simulcast for real-time viewing for those unable to attend the meeting. The ARS would like to thank the Pan-American Society and the Department of Otolaryngology-Head and Neck Surgery of the American University of Beirut, and the Middle Eastern Academy of Otolaryngology for their generous support of this webcast. The ARS would like to sincerely thank all of its corporate partners for their invaluable support. Our society could not continue to provide such high-quality meetings without your participation. We look forward to continuing to build on these relationships.



The scientific program provided one-and-a-half days of educational content in Rhinology and Skull Base Surgery. This included over 60 peer-reviewed oral presentations from many countries and three breakout rooms on the final afternoon. The Awards Committee, chaired by Marilene Wang, MD, chose the top manuscripts. First place was awarded to Do-Yeon Cho, MD for his paper "Tolerance and Pharmacokinetics of a Ciprofloxacin-coated Sinus Stent in a Preclinical Model". The runner-up was Naif Fnais, MD for "Differential innate immunity gene expression between corticosteroids responsive and non-responsive patients with chronic rhinosinusitis and nasal polyposis". Congratulations to these and all of the authors for fantastic presentations.

The 12th Annual David W. Kennedy lecturer was Ricardo Carrau, MD from The Ohio State University. Dr. Carrau is a pioneer in the rapidly advancing field of endoscopic skull base surgery. He presented a timely and well-received presentation on "Endoscopic Skull Base Surgery: State of the Art & Future Directions." Our other guest speaker, Patricia Hudgins, MD, the Director of Head and Neck Radiology at Emory University, complemented this talk with her lectures, "Radiologic Imaging of CSF Leaks and Skull Base Defects" and "Pitfalls in Radiologic Workup of the Sinuses and Skull Base".

The ARS continued the tradition of collaboration with the American Academy of Otolaryngic Allergy with a joint panel, "Pediatric Chronic Rhinosinusitis: Does it Really Exist?", that featured members of both societies in addition to the American Society of Pediatric Otolaryngology. The Fall Film FESStival, under the direction of Adam DeConde, MD, returned for the third consecutive year, with the finalists presenting fascinating videos of sinus and skull base pathology and surgery. The winner was "Unilateral approach of planum meningioma with intraoperative molecular imaging", submitted by Bobby Tajudeen, MD. Congratulations to all.

The program was full of practical and controversial topics that are important to Rhinologists today, and included:

- Are you doing Appropriate ESS? Who should have sinus surgery?
- The Socioeconomic Impact of CRS and FESS
- Skull Base Issues: What to do with the Orbit
- Timing of Sinus Surgery: How Quickly Should We Intervene?
- Sinus Disease and the Immunocompromised patient
- The Minimal Disease patient: Do I operate and when?
- The Recurrent Nasal Polyp Patient: What now?
- Sinus Surgery Mulligan: A case I would now do differently
- Failed Sinus Surgery: Revise or Advanced?
- What I learned in training but have abandoned in practice: Experience or Evidence?

The lunch breakout symposiums, including the Women in Rhinology, Mentorship, and Residents and Fellows luncheons, were huge successes with standing room only attendance.

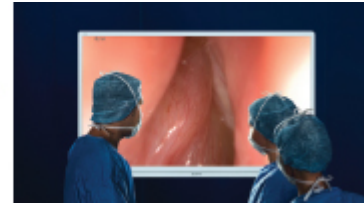If you did not have the opportunity to attend the meeting in person, the simulcast can be viewed by ARS members on the [ARS](#)

[website](#).

Thank you for the privilege of serving the members of the American Rhinologic Society as the Program Chair for the ARS fall meeting. At the conclusion of the meeting I assumed the position of President of the American Rhinologic Society. I would like to thank Peter Hwang, MD, now the Immediate Past President, for propelling the ARS forward in its growth and prominence. I look forward to serving as your society President for the upcoming year and hope that I can continue the great work done by my predecessors.



OLYMPUS
 ARE YOU READY FOR BIG SCREEN SURGERY?
 Like it at Home; Love it in the OR
4K



[Back to top](#)

ANOTHER BENEFIT OF ARS MEMBERSHIP FROM THE EDUCATION COMMITTEE: ICAR SLIDE SERIES ONLINE

Zara M. Patel, MD

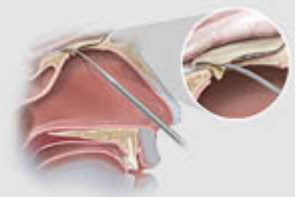
The ARS Education Committee is proud to present an all-new educational offering to our membership: a slide series based off the recently published International Consensus Statement on Allergy and Rhinology (ICAR).

This includes 376 PowerPoint slides covering all 144 rhinologic topics covered in the original document. Members can now access and download these slides for their own use in personal education, presenting topics to students and residents, or giving presentations to referring physicians within their community as part of an outreach program.

The Education Committee remains committed to providing the ARS membership with the most current and highest quality educational materials. Please visit our website <http://www.american-rhinologic.org> to access this slides series, as well as the ARS Surgical Video Library, ARS Patient Handouts, ARS Webinars and much more!



Choose a graft that handles
 like native dura mater.



RHINOLOGY PERSPECTIVES: THE RECALCITRANT NASAL POLYPOSIS PATIENT

David M. Poetker, MD

There are few patients in a rhinology practice that are more humbling than the recalcitrant nasal polyp patient. I have struggled with these patients over the years, and although I do not have any secrets, I can share some things to keep in mind when treating these patients.

Presentation of a case:

A 49-year-old male presents with a one-year history of nasal obstruction, facial pain, facial pressure, post-nasal drainage, anosmia and cough. He has a history of asthma but feels that it is well controlled. He questions whether or not he has allergies but has had no formal allergy testing in the past. He has no significant past medical or surgical history and has had no prior therapy for his symptoms. On exam, his nasal cavities are filled with polyps bilaterally.

After discussing the options, we agreed to begin conservatively with topical steroid sprays, topical antihistamine sprays and saline rinses. He returned two months later with worsening of his symptoms. We elected to get a CT scan and this revealed pan-sinusitis with a Lund-Mackay of 16. Options for additional medical management versus surgical management were discussed. Ultimately, he elected for surgery.


He underwent a "full-house FESS". He did well initially with return of his nasal airway and his sense of smell. However, over the following 12 months, he reported subjective worsening nasal obstruction, sense of smell and asthma symptoms. His nasal endoscopy showed a return of polyps bilaterally. He was treated with budesonide washes then later, straight budesonide administered in the head-hanging position. This seemed to help but did not stop the progression of his polyps recurrence.

Allergy testing was performed, showing reactivity to dust mites and tree pollen. Of note, antibody titers to Haemophilus influenzae type b and multiple strains of Streptococcus pneumoniae were not protective. He was re-immunized.

He was then seen in the emergency department for acute vision changes and peripheral numbness. Neurology suggested a diagnosis of Churg-Strauss syndrome and Rheumatology was consulted. Labs showed elevated ANCA and myeloperoxidase antibodies. A sural nerve biopsy was performed and demonstrated vasculitis with eosinophilia. The diagnosis of Churg-Strauss, now referred to as Eosinophilic Granulomatosis with Polyangiitis (eGPA), was confirmed. He was started on high dose prednisone and ultimately treated with rituximab, a monoclonal antibody against CD20.

Although eGPA is not a common diagnosis, it is one of many to keep in mind with a recalcitrant nasal polyp patient. Additional diagnoses to keep in mind include primary ciliary dyskinesia and cystic fibrosis. Usually, these patients have been diagnosed long before seeing us. But it is possible they have fallen through the cracks. Additionally, with the developments in cystic fibrosis research, new mutations have been identified. Not long ago, we diagnosed a 64-year-old woman with cystic fibrosis. Immune dysfunctions, as well as aspirin-exacerbated respiratory disease, are also diagnoses to keep in mind when treating recalcitrant polyp patients.

In these patients, we all struggle to establish a diagnosis, searching for a reason for the polyp recurrence. In such cases, we need to bring down the inflammation in the nasal cavity and paranasal sinuses. Currently, the best anti-inflammatory medications we have are corticosteroids. These act globally to reduce inflammation, decrease vascular permeability, and decrease mucin gene expression. Steroids are great short-term medications, but a terrible long-term medication. They carry many side effects that are



poorly understood. The ideal corticosteroid is one that can be delivered locally without systemic side effects.

My typical algorithm for my polyp patients is a progression through corticosteroids based on potency. Like most, I start off with a topical steroid spray. This can be like trying to melt an iceberg with a cup of coffee so I will often skip over this step if a patient's polyp burden is severe. Adding in a topical antihistamine can help improve the effect of a topical steroid but this is mostly anecdotal.

I find steroid washes to be my typical intervention. Although I think nasal sprays may be able to open the airway, using steroid washes following a thorough surgery is much more effective at keeping the disease process at bay and minimizing symptoms. Many studies have illustrated the inability of sprays and nebulized medications to penetrate the sinuses, while rinses can penetrate each and every sinus to varying degrees. The cost of the steroid wash may be prohibitive in some patients. Based on the cost differential between budesonide and prednisolone for the VA patients I treat, I have tried using prednisolone 1% ophthalmic as an additive to the saline rinses. Anecdotally, this does not seem to work as well. Upon discussing with my pharmacology colleagues, it likely has to do with the chemical formula, specifically side chains that impact the topical anti-inflammatory effects.

If the topical steroid washes do not help, I will then consider a high potency topical steroid. These include prednisolone 1% ophthalmic or betamethasone 0.1% nasal spray. The prednisolone comes as a drop, and at 1% solution, that is 10 mg of prednisolone per mL. This is potent stuff. The total daily dose is roughly 5mg of prednisolone. Keep in mind that prednisolone is the active metabolite of prednisone so anything that gets swallowed by the patient is going to get into the blood stream. It has also been shown that it is very easy to overdose on nasal drops. This may further increase the systemic steroid dose. Betamethasone, like dexamethasone, is 8 times more potent than prednisone. We use a compounded betamethasone nasal spray that is a 0.1% solution, so 1mg per mL. Using two sprays in each nostril BID is again likely equivalent to 5 mg of prednisone daily. The nice thing about the betamethasone is that the dosing is more controlled and it is easier to wean to a lower dose. If the patient improves with BID dosing, I will try to decrease to daily dosing, or even QOD dosing.

If this fails, I will consider oral medications. There is some data suggesting oral doxycycline has strong anti-inflammatory effects though I have never tried daily doxycycline for a polyp patient. Daily oral prednisone is my last resort. I will wean a patient down to the lowest prednisone dose that controls their symptoms and then maintain them on that dose daily. I don't like doing this and I make sure they are very well versed with the risks of prolonged steroid use prior to starting this regimen. Often, these patients are taking as much steroid cumulatively with repeated short courses as they do with the low dose, long-term usage. The oral steroids are always combined with a topical steroid to try to minimize the required oral dose, thus minimizing the total systemic steroid dose. If possible, I try weaning to QOD dosing. This has been shown to be kinder to the adrenal gland and cause less adrenal suppression.

There are several new drug options that have been evaluated for the recalcitrant polyp patient. The first are drug-eluting stents. This may offer the provider an array of medications that could decrease inflammation in the sinuses and shrink polyps. The second category includes monoclonal antibodies or biological drugs. These monoclonal antibodies are designed to inactivate antibodies, as well as inflammatory mediators. Omalizumab is an anti-IgE that currently is used for asthma and urticaria. This drug has data suggesting improved control of nasal polyps. Two anti-IL5 drugs, mepolizumab and rezlizumab, also have had success in the polyp patient. Dupilumab is an anti-IL4 antibody that also has been shown to improve nasal polyp size and associated symptoms.

For the most part, we do a great job with polyp patients, but we are limited in our repertoire for treating the recalcitrant nasal polyp patient. This can lead to some frustrating and humbling experiences. There does appear to be hope with the newer biologic options currently available and also those on the horizon. Additionally, the research being done, such as that on p-glycoprotein function and taste receptors, is very exciting. The future looks bright for the polyp patient and those of us that treat them.

References/further reading:

Bachert C, et al. Effect of subcutaneous dupilumab on nasal polyp burden in patients with chronic sinusitis and nasal polyposis. A randomized clinical Trial. JAMA. 2016;315:469-479.

Han JK, et al. RESOLVE: a randomized, controlled, blinded study of bioabsorbably steroid-eluding sinus implants for in-office treatment of recurrent sinonasal polyposis. Int Forum Allergy Rhinol. 2014;4:861-870.

Gevaert P, et al. Mepolizumab, a humanized anti-IL-5, as a treatment option for severe nasal polyposis. J Allergy Clin Immunol. 2011;128:989-995.

Gevaert P, et al. Omalizumab is effective in allergic and nonallergic patients with nasal polyps and asthma. J Allergy Clin Immunol. 2013;131:110-116.

Greco A, et al. Churg-Strauss syndrome. Autoimmunity Reviews. 2014;14:341-348.

Poetker DM and Reh DD. Complications in the use of systemic steroids for sinusitis. Otolaryngology Clinics of North America. 2010;43:753-768.

Van Zele T, et al. Oral steroids and doxycycline: Two different approaches to treat nasal polyps. J Allergy Clin Immunol 2010;125:1069-1076.

[Back to top](#)

35TH PAN AMERICAN CONFERENCE ON OTOLARYNGOLOGY-HEAD AND NECK SURGERY, HAVANA CUBA

Wendi Perez, ARS Executive Administrator

The Pan American Congress graciously invited several American Rhinologic Society members to participate on various panels at their recent meeting in July 2016. In addition, they offered the ARS expo space to promote and inform our international colleagues of the benefits of the society. Our booth was adjacent to the AAO-HNS's booth as well as other well-known industry partners.

Participating countries included Germany, Angola, Netherlands Antilles, Argentina, Bolivia, Belgium, Bosnia, Herzegovina, Brazil, Chile, Costa Rica, Columbia, Cuba, Ecuador, United States, Spain, El Salvador, France, Greece, Guatemala, Honduras, Hungary, Italy, Lithuania, Morocco, Mexico, Panama, Paraguay, Peru, Poland, Portugal, Puerto Rico, United Kingdom, Czech Republic, Dominican Republic, Switzerland, Turkey, Uzbekistan and Venezuela.


Overall, the US had the second highest attendance of faculty after Peru, over 80 faculty! Historically, the US is not even in the top 5 at the Pan American meetings. The AAOHNS was also well represented by their leadership, including their President (Sujana Chandrasekhar, MD) and Executive Vice President (Jim Denneny, MD). As expected, the level of expertise and talks were of the highest quality. There was also a lot of opportunity for networking with some of the most prominent otolaryngologists in Latin America. The nightly social events and tours for faculty and family, including an evening cabaret show at the famous Tropicana, were consistent with the traditions of every Pan-American Congress, going back to the very first one in Chicago in 1946, at the Palmer House, during the AAOHNS that year, and presided by the very first president of the Pan-American Association, Chevelier Jackson (USA).

Needless to say, despite all the logistical hassles of conducting a meeting like this in Cuba, the meeting was regarded as a

educational success and well appreciated by our Latin American Colleagues, including many young otolaryngologists from disadvantaged areas, who find it difficult to attend meetings outside of Latin America, and never get exposure to prominent North American otolaryngologists. Just as a point of information, the Pan-American Association provides 15 International Travel Scholarships (of \$1000) at every Congress to young otolaryngologists, as part of the Pan-American Association's philanthropic educational mission. Our combined effort and participation at this meeting really made a difference to many of these otolaryngologists seeking to improve themselves and provide the best quality of life for their patients. Hopefully, we can follow-up on this momentum with the webcast this fall.

This kind of partnership highlights the benefits of membership in the ARS, both to domestic and international physicians. Membership and partnership provide opportunities for the growth and development of us as individual physicians, and the field of rhinology as a whole.

[Back to top](#)



UPCOMING RUC SURVEY: REVALUATION OF THE FESS CODES - WHAT YOU NEED TO KNOW

R. Peter Manes, MD

The Center for Medicare & Medicaid Services (CMS) has mandated a revaluation of the endoscopic sinus surgery codes. These codes have not been revalued since the early 1990s, and came up on a CMS screen for services billed together more than 75% of the time. This will lead to the combination of some codes, as well as the possible addition of codes for new procedures. The AAOHNS and ARS will conduct a survey of practitioners this fall, and the results will be presented to the Relative Value Scale Update Committee (RUC) in January 2017.

If you receive an email requesting your participation in a survey, here are a few important points to keep in mind:

- There will be many codes being surveyed. Only fill out surveys on codes you perform and with which you are familiar. Do not feel obligated to complete surveys on procedures you do not do.
- You do not need to complete the survey in one sitting. You are able to log out and come back later as long as you use the same computer to complete your responses.
- Pay attention to the survey closure dates. You do not want to miss an opportunity to have your voice heard.
- If you have questions about completing the survey, a good resource is provided by the American Medical Association and American Academy of Otolaryngology-Head and Neck Surgery, at <http://www.entnet.org/content/obtaining-rvus-cpt-code>

[Back to top](#)

FRIENDS IN RESEARCH CAMPAIGN

We want to express our sincere thanks for the generous donations to the 2016 ARS Friends in Research Campaign.

With your support, we can continue to fund the studies that provide clinical insights valuable to the care of our patients. In the past, these efforts have helped to establish the ARS and its members as the leaders in rhinologic research. This work not only advances the care of our patients through scientific innovation, but also generates important data establishing the efficacy and cost effectiveness of our care. In the current financial landscape, this is equally important to ensure that our patients have access to the treatment necessary to address their complaints. If you are interested in donating to the ARS, please visit <http://www.american-rhinologic.org/donate>.

We thank you again for your help in this worthy endeavor.

2016 Friends in Research Fund Supporters

Platinum

John Del Gaudio, MD
James Hadley, MD
Douglas Reh, MD
James Hadley, MD
Eugenia Vining, MD
Richard Harvey, MD
Robert Kern, MD
Peter Hwang, MD
Spencer Payne, MD

Bronze

Anne Getz, MD
Thomas Higgins, MD
Keith Jackson, MD
Arthur Lauretano, MD
William Povah, MD
David Quenelle, MD
Sarah Seo, MD
Ronnie Swain, Jr., MD
Ewen Y. Tseng, MD

Gold


Rakesh Chandra, MD
Martin Citardi, MD
Subinoy Das, MD
Charles Tesar, MD
Jonathan Ting, MD
Gordon Epstein MD
Paul Goco MD
Juan Portela, MD

Friend

Henry Barham, MD
Gerald Bart, MD
Karen Bednarski, MD
Arkadiush Byskosh, MD
Clifford Timothy Chu, MD
Alen N. Cohen, MD
Firas Farhat, MD
Francisca Fernandez, MD
Waler Florez-Guerra, MD
Andrew Jacono, MD
Nedra Joyner, MD
William D. Leight, MD
Sheng-Dean Luo, MD
Jeffrey Manlove, MD
Paul Russell, III, MD
David Sherris, MD
Dole Baker, MD
Alberto Laureano
Jeffrey Myhill MD
Steven Buck, MD

Silver

Jeb Justice, MD
Donald Lanza, MD
Michelle Leonard, MD
Bradley A. Otto, MD
Belachew Tessema, MD
Elina Toskala, MD
Robert Weiss, MD
Ramzi Younis, MD



[Back to top](#)

CASE OF THE QUARTER: INVERTED PAPILLOMA MASQUERADING AS RECURRENT RESPIRATORY PAPILLOMATOSIS

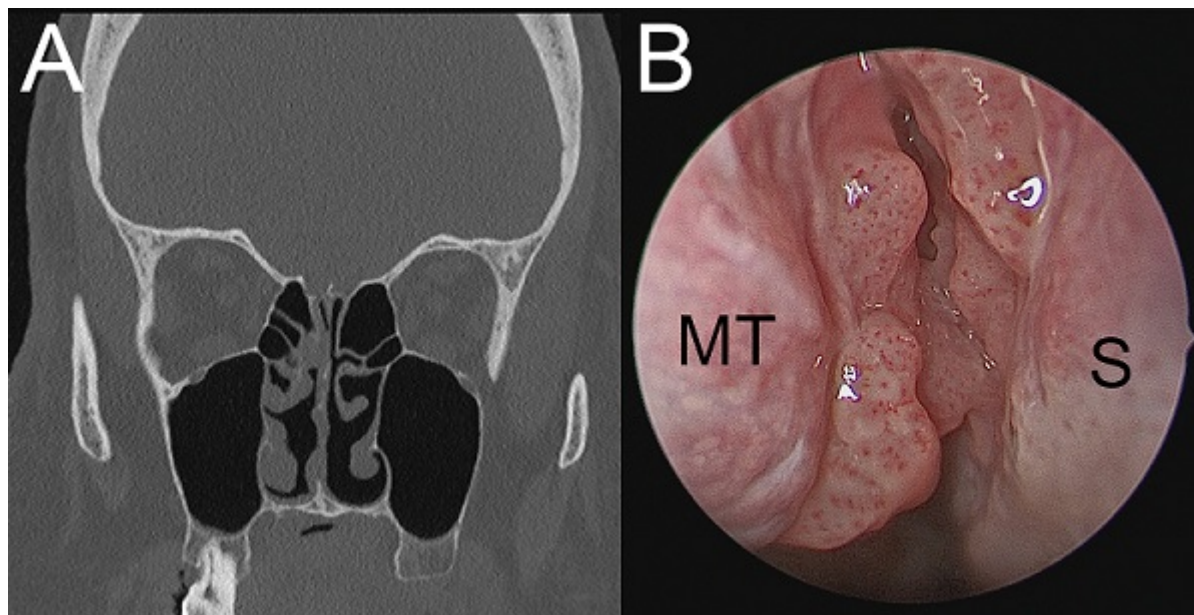
Neil S. Patel, MD and Janalee K. Stokken, MD

Case Description:

A 50-year-old male with adult onset recurrent respiratory papillomatosis was referred for rhinology consultation for multiple unilateral nasal papillomata. He had undergone endoscopic potassium-titanyl-phosphate (KTP) laser ablations for diffuse laryngotracheal disease nearly every 3 months prior. Previous biopsies of these lesions showed evidence of low to moderate grade dysplasia. Repeat airway debulking and nasal biopsy at our institution revealed squamous papillomata without evidence of dysplasia in both specimens. In-situ hybridization (ISH) studies for human papillomavirus (HPV) were negative for high-risk subtypes.

Three months later, his endoscopic examination exhibited increased nasal involvement with lesions of the middle and superior turbinates and posterior septum while sparing the nasopharynx. Computed tomography (CT) imaging showed mucosal irregularities consistent with his examination findings without hyperostosis or posterior ethmoid involvement.

Given the progressive nature of nasal disease (Figure #1), a complete endoscopic resection of the grossly involved mucosa was performed. Pathologic analysis revealed inverted type Schneiderian papilloma in all nasal specimens and benign squamous papillomata with mild to moderate atypia in the larynx and trachea. Viral ISH studies demonstrated evidence of HPV family 6 (subtypes 6 and 11) in both subsites. Repeat surgery with margin analysis is planned as frozen section pathology was equivocal and the lesion encroached the skull base.



Recurrent Respiratory Papillomatosis (RRP):

RRP is a chronic disease of viral origin affecting the larynx, trachea, and lower airways. Juvenile-onset RRP occurs from vertical transmission of HPV from mother to child and is typically diagnosed around the age of 5. Adult-onset RRP has a less clearly understood etiology but is also caused by low-risk HPV subtypes 6 and 11. Areas of the respiratory tract where ciliated and squamous epithelia are in close proximity (laryngeal ventricle, carina) are most commonly involved[1]. For papillomatosis confined to the larynx, serial endoscopic debulking achieves disease control in the majority of patients. However, up to 20% of patients may develop tracheobronchial disease necessitating more frequent or adjuvant interventions[2]. Nasal extension of RRP is rare.

While single, exophytic papillomata in the nasal vestibule are fairly common, diffuse intranasal papillomatosis has only been reported in cases without coexistent RRP. Recurrence was noted soon after initial resection in two cases, suggesting a natural history similar to RRP[3].

The rate of dysplasia in patients with adult-onset RRP is roughly 10%, with malignancy developing in up to 5%[4]. Some authors suggest that HPV-negative papilloma, tobacco use, and previous cidofovir administration may increase the risk of malignant transformation[4]. In contrast, laryngeal squamous cell carcinoma caused by HPV infection is typically associated with high-risk subtypes 16 and 31, among others[5].

Inverted Papilloma (IP):

Schneiderian papilloma refers to all squamous papillomata of the nasal or paranasal sinus mucosa. The inverted type, most commonly originating from the lateral nasal wall, is typically a single, expansile, locally aggressive tumor that remodels bone around the site of origin. The rate of transformation of IP into squamous cell carcinoma is likely between 5 and 10%[6]. HPV has been detected in up to 38% of IP specimens and some data support an association between the presence of high-risk subtypes and malignant transformation[7]. The exact role of HPV in the pathogenesis is not well defined. Treatment includes wide excision with confirmation of tumor-free margins (particularly at the site of attachment) with resection or drilling at the site of the underlying

bone, when possible, to prevent local recurrence and eliminate the risk of malignancy. A benign squamous papilloma, in contrast, can be adequately treated with narrow-field resection of involved mucosa.

Summary:

This case emphasizes the importance of having a high index of suspicion when a clinical presentation does not follow a characteristic pattern. Co-existent laryngotracheal disease, an uncommon attachment site, previous negative biopsies, and absence of classic imaging features confounded the identification of this lesion. A broad differential diagnosis and comprehensive histopathologic evaluation is important to rule out IP and malignant transformation in all nasal papilloma, particularly if high-risk HPV subtypes are identified. Wide excision with tumor-free margins is recommended to decrease the risk of recurrence.

REFERENCES

1. Kashima H, Mounts P, Leventhal B, Hruban RH. Sites of predilection in recurrent respiratory papillomatosis. *Ann Otol Rhinol Laryngol*. 1993;102(8 Pt 1):580-3.
2. Taliercio S, Cespedes M, Born H, Ruiz R, Roof S, Amin MR, et al. Adult-onset recurrent respiratory papillomatosis: a review of disease pathogenesis and implications for patient counseling. *JAMA Otolaryngol Head Neck Surg*. 2015;141(1):78-83.
3. Bleier BS, Gawthrop CS, Thaler ER, Sewell DA, Montone KT, Marvel DM, et al. Diffuse intranasal papillomatosis and its association with human papillomavirus. *Arch Otolaryngol Head Neck Surg*. 2008;134(7):778-80.
4. Karatayli-Ozgursoy S, Bishop JA, Hillel A, Akst L, Best SR. Risk Factors for Dysplasia in Recurrent Respiratory Papillomatosis in an Adult and Pediatric Population. *Ann Otol Rhinol Laryngol*. 2016;125(3):235-41.
5. Baumann JL, Cohen S, Evjen AN, Law JH, Vadivelu S, Attia A, et al. Human papillomavirus in early laryngeal carcinoma. *Laryngoscope*. 2009;119(8):1531-7.
6. Nudell J, Chiosea S, Thompson LD. Carcinoma ex-Schneiderian papilloma (malignant transformation): a clinicopathologic and immunophenotypic study of 20 cases combined with a comprehensive review of the literature. *Head Neck Pathol*. 2014;8(3):269-86.
7. Govindaraj S, Wang H. Does human papilloma virus play a role in sinonasal inverted papilloma? *Curr Opin Otolaryngol Head Neck Surg*. 2014;22(1):47-51.

[Back to top](#)

CORPORATE SUPPORTERS: THANK YOU

The American Rhinologic Society would like to express our deepest thanks and appreciation to the participants of our Corporate Partners Program. Our corporate partnerships have been invaluable in their support of ARS initiatives to promote excellence in rhinology and skull base surgery. Through our ongoing collaborative relationships, we hope to continue to mutually develop exciting and lasting opportunities for our members to enhance education, investigation, clinical care, and patient advocacy in the future.

PLATINUM

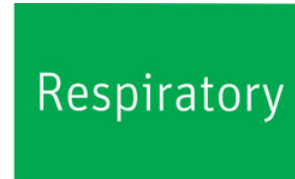Medtronic



GOLD



SILVER



BRONZE



ARS OFFICERS

- Peter Hwang, MD**
President
- Richard Orlandi, MD**
President-Elect
- Joseph Jacobs, MD**
Executive Vice President
- James Palmer, MD**
First Vice President
- Robert kern, MD**
Second Vice President
- Pete Batra, MD**
Secretary
- Rodney Schlosser, MD**
Treasurer
- Peter Hwang, MD**
Immediate Past President

BOARD OF DIRECTORS

- Rakesh Chandra, MD
- David Poetker, MD

IN CLOSING

Take a moment to explore the ARS Website where you'll find useful meeting-related information and much more.

QUICK LINKS

Donate to the ARS

[More Info](#)

ARS Summer Sinus Symposium

[More Info](#)

ARS at AAOHNS

[More Info](#)

ARS at COSM

[More Info](#)

Douglas Reh, MD
Raj Sindwani, md
Kevin C Welch, MD
Sarah Wise, MD

CONSULTANTS TO THE BOARD

David Conley, mD
Subinoy Das, MD
Deyani Lal, MD
Amber luong, mD

NOSENEWS EDITOR

R. Peter Manes, MD

ADMINISTRATOR

Wendi Perez
PO Box 495, Warwick, NY 10990
Tel:845.988.1631
Fax: 845.986.1527
wendi@amrhso.com

[Back to top](#)

Copyright ©2015 American Rhinologic Society
All Rights Reserved

american rhinologic society
nose news

[Back](#)