


## PRESIDENT'S MESSAGE



James Hadley, MD,  
FARS, President

**F**orty-nine years old and counting down to the 50<sup>th</sup>! It is an honor to serve as president of this Society following in the footsteps of so many notable rhinologists.

Amazing changes have occurred now manifesting in our new 50th anniversary logo.

This is the third change in the logo design of the ARS over the years. Initially there was the classic head mirror of the rhinologist, followed by the addition of a caduceus and nose, but now as we have become digital, our new design is appropriate for our 50th anniversary.

The specialty of Rhinology has seen a dramatic increase in interest not only among our members but also from other branches of medicine and even the lay public. Witness the development of guidelines for appropriate management of rhinosinusitis and other upper respiratory tract infections in collaboration with other specialties. Once predominantly a surgical specialty, the ARS has blossomed into the only specialty dealing with all aspects of rhinologic disorders.



planning a gala evening to celebrate 50 years of rhinology and the American Rhinologic Society. I would encourage you to mark your schedule and plan to attend this exciting event.

The Education Committee, under the stewardship of Dr. Winston Vaughan, is developing an important overview of our educational process related to rhinology and fellowship training. A planning session held at our Board of Directors meeting in New York investigated the fellowship clinical experience, application process, selection, research and publication guidelines, and surgical training. Once criteria are established, we will review and update as needed.

Patient advocacy is one of the prime functions of the ARS. The members look to the Board for direction in problems related to reimbursement to allow them to practice medicine and perform the best care for their patients. This committee, under the chairmanship of Dr. Michael Sillers and Dr. Michael Setzen, is always active and engaged with the membership. A good example was the panel discussion at the annual meeting where Dr. Sillers and Setzen discussed current questions regarding debridement, resection of concha bullosa, performance of computer aided surgery in an ambulatory surgical Center, dissection of the frontal recess and using validated patient symptom questionnaires. The use of the

## ARS 1954-2004: FIFTY YEARS OF RHINOLOGY

This enthusiasm was demonstrated at the most recent annual meeting of the Society in Orlando in September. Over 300 rhinologists attended this excellent meeting. The Program Committee was unfortunately limited to only 32 presentations from the more than 70 that were submitted for consideration. Highlights included presentations by our international honored guest, Dr. Claus Bachert from Belgium, and from our past President, Dr. Michael Benninger. Dr. Bachert's discussion of the immunology of chronic rhinosinusitis and the impact of bacterial superantigens was deeply appreciated by the attendees. Dr. Benninger provided an update on activities of the Sinus and Allergy Health Partnership. In all, your colleagues are hard at work advancing surgical techniques, basic science, immunology, microbiology and investigation of chemical mediators.

The 50th anniversary committee has been diligently working to prepare for the upcoming Golden Anniversary meeting in New York City. I have the pleasure of working with Drs Joseph Jacobs and Marvin Fried and we are investigating all the options available for an enhanced two-day meeting overlapping the weekend of September 18-20, 2004. The meeting will include panel discussions, breakout groups in addition to traditional oral presentations and poster presentations. Dr. Jacobs, the program chairperson has invited a host of international representatives to share their knowledge and expertise with our group. Additionally, we are

Audience Response System during this meeting gave excellent feedback for utilization in future planning.

This year, we are pleased to announce the formation of the Pediatric Rhinology Committee headed by Dr. Rodney Lusk. This committee will enhance the Society and will serve as a model to educate the members regarding the unique problems related to pediatric rhinology and rhinosinusitis.

Dr. Donald Lanza, our immediate Past President is still diligently working to investigate the patents that have been recently issued by the Mayo Clinic with regard to treatment of patients with fungal rhinosinusitis and the use of anti-fungal agents. His report will detail the material that has been generated and the use of funds that have been utilized to

assist in this endeavor.

I would like to extend my enthusiasm for the specialty to all of the membership and encourage you to become active within the Society. The leadership of the Society is always looking for members to become active in committees and looks to develop rhinologists into leadership roles. I know we all share the same ideals of the advancement of appropriate care for the patient with rhinologic problems, and the committee structure of the ARS is an ideal means to be able to advance these messages. You may forward your requests to Dr. Howard Levine, second Vice President and Chairman of the Committee on Committees.

*"Forty-nine years old and counting down to the 50th!"*

**JAMES HADLEY, MD, FARS**  
President

**JOSEPH JACOBS, MD, FARS**  
President-Elect

**DON LANZA, MD, FARS**  
Immediate Past President

**PAUL TOFFEL, MD, FARS**  
Past President

**MICHAEL SILLERS, MD, FARS**  
First Vice President

**HOWARD LEVINE, MD, FARS**  
Second Vice President

**MARVIN FRIED, MD, FARS**  
Secretary

**DAVID KENNEDY, MD, FARS**  
Treasurer

**BOARD OF DIRECTORS**

Stilianos Kountakis, MD  
William Bogler, MD  
Scott Graham, MD  
Winston Vaughan, MD  
Michael Sillers, MD  
Martin Citardi, MD  
Steven Marks, MD

**CONSULTANTS**

Eugenia Vining, MD  
Kathleen Yaremchuk, MD  
Peter Hwang, MD  
Richard Orlandi, MD

# ARS GOLDEN ANNIVERSARY MEETING

## MAKE PLANS NOW!



**50th Anniversary ARS Meeting**

**September 18-20, 2004**  
**New York Hilton, New York City**  
*Honored Guest: David W. Kennedy*

The American Rhinologic Society will be celebrating our 50<sup>th</sup> Golden Anniversary in 2004. The Society has organized a 3-day scientific session that will commence on the afternoon of Saturday September 18 and conclude the morning of Monday September 20 in New York City at the Hilton Hotel 1335 Avenue of the Americas between 53 and 54 Sts. Our meeting will coincide with the American Academy of Otolaryngology Fall meeting. The venue of New York City as well as the simultaneous Academy meeting will attract many national and international attendees. David Kennedy will be our Guest of Honor and the faculty will include an unprecedented number of national as well as international experts within the field of Rhinology.



Jan Gosepath is coordinating the international faculty which includes: Heinz Stammberger, Wolf Mann, Valerie Lund, Claus Bachert, Christian Buchwald, Silvain Lacroix, Metin Onerci, Paolo Castelnovo, Ranko Mladina, Vladimir

Continued, Page 3



# GYRUS ENT

The American Rhinologic Society would like to thank Gyrus ENT for partnering with the ARS Newsletter for 2004

The American Rhinologic Society would like to thank Abbott Labs for partnering with the ARS Newsletter, Spring 2004

## UPCOMING



## EVENTS

April 15, 2004  
April 30- May 1, 2004

Abstract Deadline, ARS Golden Anniversary Meeting  
ARS Spring Meeting (COSM), JW Marriott  
Desert Ridge Resort and Spa, Phoenix, AZ

June 1, 2004

ERS Meeting, Istanbul, Turkey

**September 18-20, 2004**

**ARS Golden Anniversary Fall Meeting, NYC**

November 1, 2004

Abstracts Due, Spring Meeting, 2004

December 15, 2004

Membership Dues Due, 2005

# SINUS & ALLERGY HEALTH PARTNERSHIP

J. David Osguthorpe, MD, FARS



The Sinus and Allergy Health Partnership (SAHP), comprised of representatives from the American Rhinologic Society (ARS), the American Academy of Otolaryngology-Head and Neck Surgery (AAO-HNS) and the American Academy of Otolaryngic Allergy (AAOA), remains active on your behalf. Such activities include presentations at various meetings, publications, a “study group” on medical patent issues, and a research project. The following is a brief on the aforementioned.

1. As for the past 4 years, “volunteers” (Drs. J. Hadley, M. Benninger and D. Osguthorpe) from the SAHP presented a breakfast mini-seminar at the Annual Meeting of the AAO-HNS, the topic this year being chronic rhinosinusitis. Attendance represented the largest audience for an AAO-HNS breakfast mini-seminar, and encourages the SAHP to continue this offering.

2. In the September issue of Otolaryngology-Head and Neck Surgery, the Chronic Rhinosinusitis Task Force of the SAHP published a supplement on “Adult Chronic Rhinosinusitis: Definitions, Diagnosis, Epidemiology and Pathophysiology” (lead author – Dr. M. Benninger). Such framed the salient issues, and current literature, and pointed the way toward the future clinical and research studies that will likely be needed before the federal Food and Drug Administration accepts applications for specific drug therapies for chronic rhinosinusitis.

The SAHP will be updating its’ guidelines on acute bacterial rhinosinusitis (lead authors – Dr. J. Anon, M. Jacobs, M. Poole; initially published in 2000) in the January 2004 issue of Otolaryngology-Head and Neck Surgery. Both the aforementioned endeavors involved input from multiple specialties.

3. The AAO-HNS and ARS have requested both input and financial support from the SAHP for a “study group” (chair – Dr. B. Marple) on the implications of patents on otolaryngology procedures or practices. The recent acquisition of 3 patents on the treatment of fungal rhinosinusitis is an example. A literature search is underway, and the opinions of appropriately qualified attorneys have been sought. To date, the SAHP has contributed the financial backing (\$30,000), the AAO-HNS the support personnel and the ARS (under Dr. D. Lanza) the majority of literature reviewers for this endeavor.

4. A major reason most Phase 2 and 3 pharmaceutical trials on rhinosinusitis are conducted outside of the United States is our difficulty in recruiting patients for double (maxillary) tap investigations, and also the paperwork and occasional restrictions placed by the Internal Review Boards of academic institutions. The SAHP, after consultation with representatives of the federal Food and Drug Administration (FDA), has embarked on a clinical study comparing the bacteria acquired by direct maxillary tap with those from an endoscopically-guided microswab sampling, or an aspiration, of the middle meatus (in patients with clinical and radiographic manifestations of rhinosinusitis). A correlation of 85% or better between the 2 methods may well convince the FDA to allow carefully performed endoscopically obtained cultures to be substituted for tap cultures in Phase 2/3 clinical trials.

For further information regarding the SAHP, feel free to contact its’ staff, William Shawver, or Executive Director, Jamie Lucas, at 202-955-5010 (fax 202-955-5016; 1990 M Street, NW, Suite 680, Washington, DC 20036). In addition, the SAHP Board of Directors, comprised of Drs. Michael Benninger, Ivor Emanuel, James Hadley, David Kennedy, Donald Lanza, Bradley Marple, and David Osguthorpe, are available for specific issues.

JOIN THE ARS!  
FOR YOUR PATIENTS!  
FOR YOU!



## 50TH, CONTINUED

Kozlov, Peter Clement, P J Wormald and Carlos Cuiilty-Siller. This list will continually be updated.

The scientific program will include free paper sessions, instructional courses, moderated sessions, video and breakfast symposia as well as poster presentations. A number of social programs will be available to attendees and their guests including a gala dinner event.

Hotel accommodations will be available through the American Academy of Otolaryngology as well as through the NYC conventions and visitors bureau, [www.nycvisit.com](http://www.nycvisit.com) or email [palvarez@nycvisit.com](mailto:palvarez@nycvisit.com). This office can arrange budget accommodations within the area of New York City hosting the ARS as well as the Academy meeting.

Abstract submission through the e-module program on the ARS web site, [www.american-rhinologic.org](http://www.american-rhinologic.org), will close on April 15, 2004.

Our society continues to focus on providing our membership with quality scientific and educational programming. Approximately 70 abstracts were submitted to be evaluated by our Program Committee for presentation at COSM 2004. The core group of these abstracts continues to evolve with superb basic science material as well as thoroughly well documented clinical studies. The presentations include a significant number of topics relating to the evolving field of the inflammatory pathway and this potential relationship to the pathophysiology of Chronic Rhinosinusitis. In addition, material discussing medical management, surgical therapy with and without image guidance, novel techniques and radiologic evaluation have been included within the program. Finally, an excellent group of both basic science and clinical poster presentations were for review throughout the scientific session as well

Three panel discussions will highlight the recently formed Pediatric Committee of the ARS, the treatment of Pediatric Rhinosinusitis" focusing management of this disease process between adults a panel entitled "New guidelines defining chronic Bradley Marple and Berrilyn Ferguson. Michael Patient Advocate Committee, will present "Utilizing pertinent for all of us. Drs. Mike Sillers and Don

Dr. Allen Seiden, Chair of the Awards annual ARS Spring Research Award. The society Audience Response System which was successfully mechanism provides us with instant feedback on issues.

I want to thank the Program Committee for includes Drs. Mike Sillers, Rich Orlandi, Todd Kountakis, Kelvin Lee, Todd Loehrl and Jim Palmer. Additional moderators include Drs. Andrew Lane, Tim Smith, BJ Ferguson, Andrew Murr, Pete Batra, Roy Casiano, Robert Kern, Kathy Yaremchuk, Karen Fong, Richard Lebowitz and Jay Dutton.

Plan on attending the ARS Spring 2004 COSM Meeting April 30-May 1. We have an excellent educational opportunity for you and the hotel is a fabulous venue for this event.



program. Dr. Rodney Lusk, the Chair of the and Dr. Michael Poole will present "An update on on the different aspects of medical and surgical and children. Dr. Howard Levine will moderate rhinosinusitis" including Drs. Michael Benninger, Setzen M. D., the newly appointed chair of the Correct CPT Coding and Documentation" which is Lanza will join him as panelists.

Committee, is evaluating the abstracts for our is presently working with the vendor of the utilized during the Fall Meeting in Orlando. This a number of important educational and structural

their work evaluating the submissions. This group Kingdom, John Delgaudio, Peter Hwang, Stil They will also moderate during the spring session.

## April 30

### Event

- 1:00PM ARS Scientific Session COSM Program: Opening Remarks  
1:10 **Frontal Sinus Surgery**  
The Indications and Role of Osteoplastic Flap for Obliteration of the Frontal Sinus in the Era of Image Guided Surgery  
1:15 Surgical Decisions in Management of Frontal Sinus Osteomas  
1:20 Causes of Frontal Sinus Failure in Endoscopic Sinus Surgery  
1:25 Chronic Frontal Sinusitis: Is endoscopic surgery a risk factor?  
1:30 *Discussion*  
1:45 **Radiologic Evaluation**  
Isolated Inflammatory Sphenoid Sinus Disease - A Revisitation of CT Indications Based Upon Presenting Findings  
1:50 Anatomic Measurements for the Modified Lothrop Procedure  
1:55 Orbital Volumetric Analysis of Allergic Fungal Sinusitis Patients with Proptosis Before and After Endoscopic Sinus Surgery  
2:00 Utility of Sagittal Reformatted Computerized Tomographic Images in the Evaluation of the Frontal Sinus Outflow Tract  
2:05 Sagittal & Coronal Dimensions of the Ethmoid Roof:  
2:10 A Radiologic Study  
2:25 *Discussion*  
**Panel: Guidelines for Management of Chronic Rhinosinusitis**  
New Guidelines Defining Chronic Sinusitis  
The Role of Bacteria and the Superantigen in Chronic Sinusitis  
Fungus: Its Role and the Treatment in Chronic Rhinosinusitis  
The Role of Bone Infection in Chronic Rhinosinusitis  
3:10 Case Presentations  
3:30 **Break**  
Endoscopically Guided Aerobic Cultures in Post-Surgical Patients with Chronic Sinusitis  
3:35 Adverse Effects of Quinolone Antibiotics in Treatment of Sinusitis

### Presenters, Moderators & Discussants

- James Hadley, MD & Joseph Jacobs, MD  
Andrew Lane, MD & John DelGaudio, MD  
  
Ashutosh Kacker, MD  
Alexander Chiu, MD  
John DelGaudio, MD  
Tamer Ghanem, MD  
  
Richard Orlandi, MD & Robert Kern, MD  
  
Young An, MD  
Firas Farhat, MD  
  
Rodney Schlosser, MD  
  
Seth Kanowitz, MD  
  
Mark Zacharek, MD  
  
Howard Levine, MD  
Michael Benninger, MD  
Bradley Marple, MD  
Berrilyn Ferguson, MD  
Howard Levine, MD  
Howard Levine, MD  
  
Robert Sonnenburg, MD  
  
Christopher Church, MD

3:40	Treatment of Chronic Rhinosinusitis Exacerbations due to Methicillin-Resistant Staphylococcus Aureus with Mupirocin Irrigations	C. Arturo Solares, MD Erica Robb Thaler, MD
3:45	Use of an Electronic Nose to Diagnose Bacterial Sinusitis	
3:50	<i>Discussion</i>	Andrew Murr MD & Richard Lebowitz MD
<b>Radiologic and Clinical Correlation</b>		
4:10	Correlation of Degree of Frontal Sinus Disease to the Presence of Frontal Headache	John DeIGaudio, MD
4:15	Correlations Between Bone SPECT and CT Imaging of the Sinuses in Chronic Sinusitis	Peter Catalano, MD Samer Fakhri, MD
4:20	Challenges in the Management of Sphenoid Inverted Papilloma	
4:25	Increased Role of the Otolaryngologist in Endoscopic Pituitary Surgery: Endoscopic Hydro-examination of the Sella	Marc Dubin, MD
4:30	<i>Discussion</i>	
<b>Olfaction</b>		
4:45	Development of Transgenic Mouse Models for the Study of Human Olfactory Dysfunction	Karen Fong, MD Andrew Lane, MD
4:50	The Effects on the Olfactory Neuroepithelium and Olfactory Bulbs of the Sprague-Dawley Rat Following Oral Administration of Zinc	Anthony Albert Carboni, D.Ed.
4:55	<i>Discussion</i>	
5:00	ARS Business Meeting	

## **May 1**

8:00 AM	Opening Remarks	S. Kountakis, MD & P. Hwang, MD
<b>Pathophysiology and the Inflammatory Pathway</b>		
8:05	TGF- $\beta$ as a Marker for Eosinophil Mediated Inflammation in Chronic Rhinosinusitis and Nasal Polyposis	Stilianos Kountakis, MD
8:10	Tissue Damage Induced by Eosinophil Peroxidase in Patients with Chronic Rhinosinusitis	Martin Citardi, MD Siew Shuen Chao, MD
8:15	Cysteinyl Leukotriene 1 Receptor Expression in Nasal Polyps	
8:20	Expression, Localization and Significance of Vascular Permeability / Vascular Endothelial Growth Factor (VPF/VEGF) in Nasal Polyps	Jan Gosepath, MD James Palmer, MD & Jay Dutton, MD
	<i>Discussion</i>	
8:25	Fungi - A Normal Content of Human Nasal Mucus	Dr. Andreas Lackner
8:45	Evidence of Bacterial Biofilms in a Rabbit Model of Sinusitis	Joel Perloff, MD
8:50	Superantigens and Chronic Sinusitis II: Analysis of T-Cell Receptor V $\alpha$ Domains in Nasal Polyps	David Conley, MD
8:55	MUC5B Secretion is Upregulated in Chronic Sinusitis Compared to Controls	Mr. Harishnath Viswanathan
9:00	<i>Discussion</i>	
9:05	<b>Panel: Update on the Treatment of Pediatric Rhinosinusitis</b>	Rodney Lusk, MD
9:25	Medical & Surgical Therapy	Michael Poole, MD & Rodney Lusk, MD
	<b>Break</b>	
<b>Techniques and Evaluation</b>		
10:00	Is Helicobacter Pylori Really Present in the Adenoids of Children?	Roy Casiano, MD & Kelvin Lee, MD
10:20	Pharyngeal pH Probe Findings in Patients with Postnasal Drainage	Mohamed Bitar, MD
10:25	Real-time Image Guided Endoscopic Sinus Surgery	Todd Loehrl, MD
	Allergic Fungal Sinusitis Cases and the 32 <sup>nd</sup> Parallel Latitude	
10:30	<i>Discussion</i>	Vijay Anand, MD
10:35	Revision FESS: Objective and Subjective Surgical Outcomes	Scott Manning, MD
10:40	Endoscopic Orbital Decompression for Graves Ophthalmopathy	Tim Smith, MD & Todd Loehrl, MD
10:50	Inspiratory and Fixed Nasal Valve Collapse--Clinical and Rhinometric Assessment	Kevin McMains, MD
10:55	<i>Discussion</i>	Jan Kasperbauer, MD
11:00	Poster Presentation and Award	Ramakrishnan Vidyasagar, MBBS
11:05	<b>Panel: Utilizing Correct CPT Coding and Documentation to Enhance Patient Care</b>	Kingdom, Yaremchuk & Sillers, MDs
11:15		
11:30	Closing Remarks	M.Setzen, M.Sillers, D.Lanza, MDs
12:00		

# PATIENT ADVOCACY: POST OP DEBRIDEMENT

Jordan Josephson, MD, FARS

## **Post-Operative Care: Traditional Teaching vs. Insurance Companies Dictums A Source Of Continued Confusion**

Functional Endoscopic Sinus Surgery (FESS) has been a great advance in medicine. Three reasons for this include: more accurate diagnosis of sinus disease, FESS techniques in the operating room, and most importantly a means to provide meticulous post-operative care in the immediate post-op period (30-60 days) and to control long term chronic disease, affording patients a better quality of life.

Recently a study was done stating debridements were performed an average of 1.2 times after FESS. This is misleading because it includes input from the greater than 50% of physicians that do not perform or bill for 31237 because of lack of reimbursement or fear of unwarranted retribution by the insurers. The insurance companies have incorrectly interpreted this statistic to the patients' detriment. One or two debridements will not prevent scar tissue, recurrence of polyps or control chronic disease.

Dr. Brent Senior in the July 2001 issue of Nose News discussed that the post-operative period (30-45 days) usually consists of 3-7 debridements. This is more accurate. However, some insurers and insurance physician consultants consider this the total for the patient's lifespan. They deem further medical care unnecessary. This is inaccurate and should only be a guideline in the immediate post-operative period.

The American Academy of Otolaryngology has done extensive work to get the global period for FESS to zero. This was felt necessary so that otolaryngologists would perform the necessary debridements of infection, scar tissue and recurrent polypoid tissue in both the immediate post-op period (30-45 days) and afterwards depending on the case. There are many patients that need meticulous long-term care after the immediate post-

operative period, especially those with chronic diseases including fungal sinusitis, bacterial chronic infection, recurrent polyposis and Sampters triad. Some of these patients may at certain times even require daily or weekly debridements. The physician should concurrently prescribe a complete medical regimen to control the chronic disease process and to decrease the need for frequent debridements, which are an adjunct to medical therapy. It is these patients that will suffer the most should care not be provided when necessary beyond the immediate post-operative period.

Quality care is expensive. Many insurers around the country have gotten around the zero global period by allowing care to be rendered by their contracted providers every 90 days. Insurance carriers fear that 31237 will be over utilized. To prevent this they have made physicians feel guilty about billing for it labeling them as "overutilizers." Similarly, others perform the procedure but don't bill for it. Since when should physicians be ashamed and afraid to provide quality care? This is unfair to the patients that need and are not receiving follow-up debridements as their quality of life will probably be diminished, they may be at increased risk of complications of sinus disease and they may have an increased need for revision surgery in the operating room. Hopefully the insurance companies will come to realize, as did the original HCFA reviewers, that it is important to provide this care. Furthermore, it should actually decrease the costs of care long term and significantly improve the quality of life for the patient. It is up to us to provide quality care and to help patients get the insurance companies to understand that quality medical care is important.

This still remains a dilemma, but hopefully insurance companies and physicians alike will do the right thing. They will place the patient first and provide them with the best quality of care possible.

## 2004 ARS CORPORATE AFFILIATES

Diamond (\$80,000)

Merck

Platinum (\$10,000)

Aventis

Gyrus ENT

Gold (\$5,000)

Karl Storz Endoscopy America

SinusPharmacy



Silver (\$2,500)

Bayer

Medtronic-Xomed

Ortho McNeil

Richard Wolf Medical Instruments

Bronze (\$1,000)

GE Medical Systems

Abbott Laboratories

Friend (\$500)

Brainlab

# CASE OF THE QUARTER: SPHENOID MASS

Richard Orlandi, MD, FARS and Becky Massey, MD

A 65-year-old man was referred for management of a sphenoid sinus mass. He had presented to another otolaryngologist with chronic symptoms of facial congestion and headache. A CT scan was performed and a sphenoid sinus mass was found. Endoscopic biopsy via a transtethmoid approach demonstrated inverted papilloma with foci of carcinoma-in-situ. He was then referred to our institution for further management.

The patient had no visual symptoms and examination showed normal cranial nerve function. Endoscopic examination revealed a papillomatous lesion within the sphenoid sinuses extending into the posterior ethmoid sinuses and sphenoidal recesses bilaterally. Review of the CT scan demonstrated obliteration of the intersinus septum and thinning of the lateral sphenoid sinus walls bilaterally (Figure). There was also extension into the posterior ethmoid cells. The MRI showed tumor filling the sphenoid sinuses.

After discussion of endoscopic and open approaches, the patient agreed to an endoscopic approach for resection of the mass. Image guidance was used given the proximity to the carotid arteries and optic nerves. The mass was approached with endoscopic total ethmoidectomies bilaterally. Tumor extended to the basal lamellae bilaterally and the middle and superior turbinates were resected to the skull base. Mucosa was elevated from the lamina papyracea bilaterally to obtain an anterior-lateral margin. The posterior portion of the perpendicular plate of the ethmoid and the keel of the vomer were removed with 1 cm. anterior-medial margins. The sphenoid face was then taken down to the level of the floor and all areas of tumor were removed with a 5 mm. margin inferiorly and superiorly. The tumor was peeled off the carotid artery and optic nerve bilaterally. The right carotid artery was dehiscent and the tumor was peeled off the adventitia without injuring the artery. Frozen sections were taken from the anterior, superior and inferior margins and showed no residual disease.

The patient had an unremarkable postoperative course. There were no visual or neurologic deficits. Final pathology revealed no malignancy. There were foci of severe dysplasia in the sphenoid and left middle turbinate specimens. All margins were free of tumor. The patient has been followed with endoscopic exams at quarterly intervals and has been free of disease for 18 months.

## Discussion

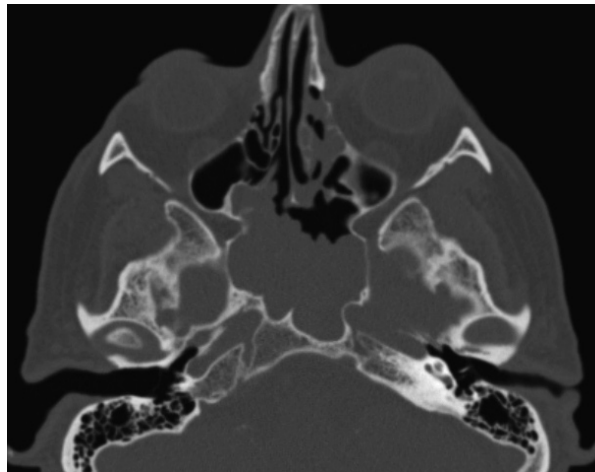
Inverting papilloma is a benign, locally aggressive tumor of the sinonasal tract that requires complete removal, due to both its tendency to recur and its association with squamous cell carcinoma. Long thought to be primarily due to human papilloma virus infection,<sup>1</sup> early evidence suggests an inflammatory etiology as well.<sup>2-4</sup> Endoscopic resection of inverted papilloma was first suggested over a decade ago<sup>5, 6</sup> and, since that time, has been

questioned by a number of experts.<sup>7</sup> In contrast, numerous authors over the last decade have presented their series of successful resections of inverted papilloma.<sup>8, 9</sup>

The case presented above illustrates the utility and efficacy of an endoscopic resection. Alternatives to this approach include a lateral rhinotomy, midfacial degloving, transpalatal approach, or subcranial approach. Each of these open procedures would have introduced much more morbidity without a significant improvement in visualization of tumor margins or in the ability to resect them. The endoscope's magnification and illumination afforded the ability to better visualize tissue margins and was indispensable in delineating the tissue planes during removal of

the tumor from the dehiscent carotid artery. This improved visualization is a significant advantage over resection using a headlight and surgical loupes.

Inverted papilloma of the sphenoid sinus is fortunately rare and its management presents challenges as far as the structures of the lateral sphenoid wall. Endoscopic resection affords the surgeon precise visualization of tumor and normal structures. Open approaches, with their attendant morbidity, add no advantage in this location. This case adds further support for endoscopic resection of



inverted papilloma.

## References

1. Beck J.C., McClatchey K.D., Lesperance M.M., et al. Presence of human papillomavirus predicts recurrence of inverted papilloma. *Otolaryngol Head Neck Surg* 113:49-55, 1995.
2. Orlandi R.R. and Terrell J.E. Sinus inflammation associated with contralateral inverted papilloma. *Am J Rhinol* 16:91-95, 2002.
3. Michaels L. and Young M. Histogenesis of papillomas of the nose and paranasal sinuses. *Arch Pathol Lab Med* 119:821-6, 1995.
4. Deitmer T and Wiener C. Is there an occupational etiology of inverted papilloma of the nose and sinuses? *Acta Otolaryngol* 116: 762-5, 1996.
5. Waitz G. and Wigand M. E. Results of endoscopic sinus surgery for the treatment of inverted papillomas. *Laryngoscope* 102:917-22, 1992.
6. Stankiewicz J. A. and Girgis S. J. Endoscopic surgical treatment of nasal and paranasal sinus inverted papilloma. *Otolaryngol Head Neck Surg* 109:988-95, 1993.
7. Bielamowicz S., Calcaterra T.C., Watson D. Inverting papilloma of the head and neck: the UCLA update. *Otolaryngol Head Neck Surg* 109:71-6, 1993.
8. Tufano R. P., Thaler E. R., Lanza D. C., et al. Endoscopic management of sinonasal inverted papilloma. *Am J Rhinol* 13:423-6, 1999.
9. Han J.K., Smith T. L., Loehrl T., et al. An evolution in the management of sinonasal inverting papilloma. *Laryngoscope* 111:1395-1400, 2001.

American Rhinologic Society  
Marvin P. Fried, MD, FACS  
Department of Otolaryngology  
Montefiore Medical Center  
3400 Bainbridge Avenue, 3rd Floor  
Bronx, New York 10467

PRSR STD  
US POSTAGE  
PAID  
Rochester MN  
Permit No. 722

### UPCOMING RHINOLOGY MEETINGS & COURSES

**\*Penn International Rhinology Course** March 11-13, 2004  
University of Pennsylvania, **Contact: Bonnie 215.662.2137**

**\*Advanced Functional Endoscopic Sinus Surgery** April 1-3, 2004  
Georgia Nasal & Sinus Institute, **Contact: 912.350.3655**

**\*The Carolina Course in Sinus Surgery and Facial Plastic Surgery** April 2-3, 2004  
University of North Carolina, **Contact: Kathy 919.966.3342**

**\*New York Rhinology and Sleep Disordered Breathing Update** April 2-3, 2004  
NYU and Albert Einstein, **Contact: Kathy 212.263.5294**

**\*Current and Advanced Techniques in FESS** July 21-24, 2004  
St. Paul's Sinus Center, UBC, Vancouver, **Contact: Luke 604.822.6434**

*If you would like to have your upcoming rhinology meeting noted here, simply provide the editor with pertinent information:  
[newsletter@american-rhinologic.org](mailto:newsletter@american-rhinologic.org)*

*The American Rhinologic Society does not endorse these meetings but simply provides the list as a service to its members*

American Rhinologic Society Newsletter  
Editorial Office  
University of North Carolina, CB 7070, Chapel Hill, NC 27599-7070  
Editor: Brent A. Senior, MD, FACS  
FAX: 919.966.7941

Email: [newsletter@american-rhinologic.org](mailto:newsletter@american-rhinologic.org)

*The Editor would like to thank Molly Reid & SinusPharmacy for design assistance for ARS Nose News*